11

Management of Complications

In this chapter we describe the common modes of failure of the OUKA and suggest ways of dealing with them. We also discuss why they occur and how they can be prevented.

Complications occur more commonly in the hands of learners than in those of the experienced surgeons whose reports are published in the literature. As a result, the incidence of complications is lower in published cohort series compared to national registers

In Table 11.1 we show the incidence of the various different complications in two different series, the NJR and our own series out to 15 years.

Table 11.1 Reasons for reoperation in the designer series and NJR based on Patient Time Incident Rate (PTIR).

Indication for re-operation / revision	Designer Series Phase 3, at mean 10 years	NJR Data at 10 years
Progression of arthritis in the lateral compartment	2.4 %	2.6 %
Bearing dislocation	0.7 %	0.1 %
Unexplained pain	0.7 %	1.9 %
Infection	0.6 %	0.5 %
Aseptic loosening	0.2 %	3.6 %
Fracture		0.2 %
PFJ problem		
Other	0.6 %	3.5 %

In the long term, the commonest cause of failure is progression of arthritis in the lateral compartment although the incidence is low. In the NJR, there is a much higher incidence of revision for pain or loosening than in the designer series. This is likely to be, at least in part, because of misinterpretation of tibial radiolucency. Inexperienced surgeons often consider the common stable radiolucency to be a source of pain or indicative of loosening when the evidence suggests it is not. The dislocation rate of 0.1% in the NJR is surprisingly low, perhaps because surgeons do not consider treatment of a dislocation to be a revision. There are no failures because of patellofemoral joint problems or wear in either series.

Infection

The incidence of infection after UKA is about half that after TKA [1]. The methods of investigation of suspected infection are the same in OUKA as in TKA except that radionuclide uptake studies are not helpful. After OUKA, activity in the bone beneath the implants persists for several years, so the presence of a 'hot' area on the scan is not necessarily evidence of infection (or loosening). The C-reactive protein or erythrocyte sedimentation rate are the most useful diagnostic tests but may not be positive in the first 2–3 weeks. We do not have any experience of using the new synovial fluid markers to diagnose suspected prosthetic joint infection after UKA.

Treatment

Acute infection

In the early postoperative period, acute infection is diagnosed and treated in the same way as after TKA. Early open debridement and change of meniscal bearing and intravenous antibiotics can arrest the infection and save the arthroplasty. The use of arthroscopic lavage is not recommended as it is not as reliable as open debridement and exchange of bearing.

Late infection

Failure of treatment of an acute infection, or infection of later onset, is diagnosed from the clinical and radiological signs and bacteriological studies, as in TKA. The earliest radiological signs may be in the retained compartment. Figure 11.1(a) shows thinning of the articular cartilage and juxta-articular erosions of the lateral joint margin of an infected knee after medial OUKA; evidence of chondrolysis by the infecting organism and chronic synovitis. (Note that acute rheumatoid synovitis can produce a similar appearance.) The eventual appearance of thick (>2 mm), ill-defined progressive radiolucencies beneath the components (Fig. 11.1(b)), quite different from the thin radiolucent lines with radiodense margins that outline most normally functioning OUKA, is diagnostic.

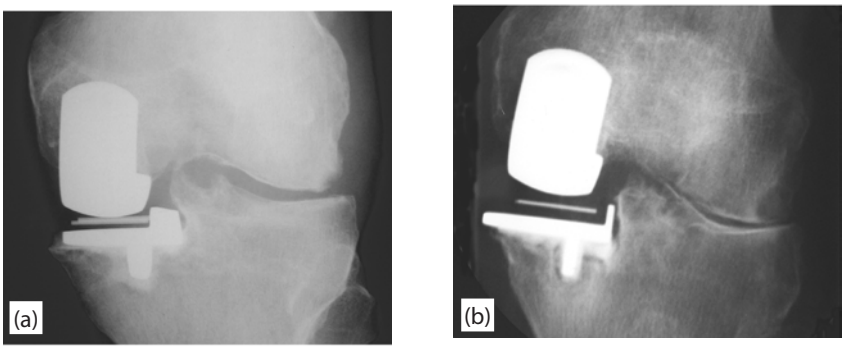

Figure 11.1 (a) The earliest radiographic sign of infection may be the appearance of subchondral erosions in the retained compartment of the knee. (b) The radiolucencies under the tibial plateau are more than 2 mm thick and are not defined by a radiodense line. They are different from the common 'physiological' radiolucent lines and suggest infection and/or loosening.

Treatment is by removal of the implant and excision of the inflammatory membrane, followed by one- or two-stage revision to TKA. We prefer the two-stage procedure, with removal of the implant and excision of the articular surfaces of the retained compartment at the first stage. An antibiotic-loaded spacer is left in the joint to maintain the gap and deliver high doses of antibiotic until the infection is eradicated and the second stage can be safely undertaken. Three types of spacers can be used (Fig. 11.2). We favour a bicompartmental spacer as this allows removal of all infected articular cartilage at the first stage. The spacer can be static or articulating depending on surgeon preference. The second-stage TKA may require a stemmed tibial implant (with additional medial augments) if there is substantial tibial bone loss.

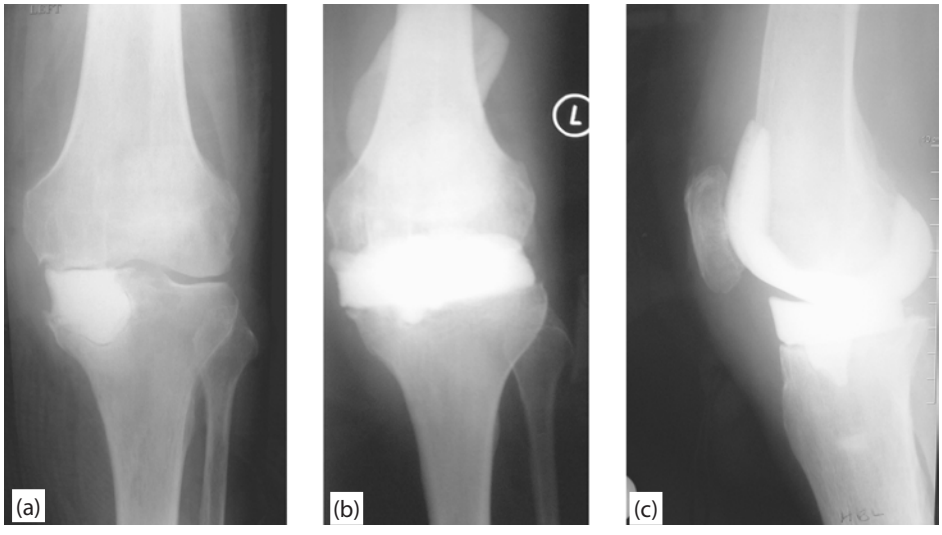

Figure 11.2 Spacers are used between the procedures of a two-stage revision for infection: (a) unicompartmental (not recommended as bacteria can persist in retained cartilage); (b) simple bicompartmental; (c) articulating.

Medial tibial plateau fracture

The 2014 NJR report gives a figure of 0.30 revisions for periprosthetic fracture per 1000 years (95% CI 0.24 – 0.37) in UKA (Fig. 11.3(a)) [2]. Registers however underestimate the incidence of fracture as many are internally fixed rather than revised. In our series of 1000 Phase 3 cemented OUKAs, we did not encounter a single fracture [3]. Similarly with the current design of cementless OUKA, we have not encountered any tibial plateau fracture. Fractures occur with all types of UKA, for example four plateau fractures occurred in 62 UKAs reported by Berger *et al.* [4] and there are other occasional reports in the literature [2, 6-9]. We have reported on a series of eight cases of tibial plateau fractures after Oxford UKA (which occurred over a period of seven years) collected from various institutions in the UK [8]. The study confirmed that these fractures are rare and tend to occur in inexperienced hands with both cemented as well as cementless implants.

Despite the very few fractures in the published reports of OUKA cohorts, several have been reported to us by other users and we believe that the complication is more common than the literature suggests, particularly among surgeons beginning to do unicompartmental arthroplasty, in populations with constitutionally small tibiae (e.g. Asian populations) and following cementless fixation.

Cause

It seems likely that plateau fractures either occur intraoperatively or are a result of severe weakening of the bone caused intraoperatively. They are either diagnosed intraoperatively or present later, commonly at 2–12 weeks postoperatively (Fig. 11.3(a)). If the fracture is initially undisplaced, it may not be visible on the immediate postoperative radiographs, only appearing later when weight-bearing has caused displacement, and postoperative pain and deformity have drawn attention to the problem.

Weakening of the condyle

Weakening of the condyle by removal of its articular surface and subchondral bone plate is probably the main reason for fracture. Since this is unavoidable, great care should be taken to avoid any additional weakening of the bone. We believe that the most potent cause of fracture is damage to the posterior tibial cortex and the cancellous bone by vertical saw cuts that go deeper than they need or if the keel slot breaks through the posterior cortex (Fig. 11.3(c)). Even the two small holes made in the anterior cortex by the nails that fix the tibial saw guide have been shown to decrease the strength of the tibial condyle [2, 6]. Although we have used this method of fixation in all phases of the OUKA without complication, we now use only one nail.

The more bone that is removed from the condyle, the weaker is the remainder; therefore the surgical objective should be to remove as little as possible. It is an advantage of meniscal-bearing arthroplasty that polyethylene only 3 or 4 mm thick can be used safely. This advantage should be exploited by removing as little tibial plateau as possible.

The smaller the tibia, the less bone can be safely removed from it. This may explain why more fractures have been reported to us from Asian countries where many adults are of small stature. It is particularly important in small patients that the horizontal tibial saw cut should aim to accommodate a thin bearing which can be as little as 3 mm thick (see Chapter 6). Cadaver studies have shown that the load to fracture is significantly lower following cementless fixation than cemented so surgeons must be more careful with cementless fixation [10]. This is a particular problem when surgeons with a large experience of the more forgiving cemented fixation swap to cementless.

Finite element analysis (FEA) work shows that the strain in the proximal tibia and thus the risk of fractures is significantly elevated by (a) a deep tibial resection; (b) too medial or too deep a vertical cut (Fig. 11.4) [11]. This in turn diminishes the